

**PATIENT PRESENTING CLINICAL SIGNS**

Oliver Woconish acute chronic cough Hx of collapsing trachea HM 4/6 concern for R side enlargement and progressed dz Current meds Hydrocodone

**SPECIES ULTRASONOGRAPHIC EXAMINATION OF THE HEART**

Canine

**BREED**

Chi

**SEX**

MN

**AGE**

13

**WEIGHT**

15

CANINE CARDIAC PARAMETERS	MR VMAX (m/s)	TR VMAX (m/s)	LA/AO M-mode	LA/AO (Heart Base; Swe)	FS (%)	EF (%)	EPSS (cm)
NORMAL PARAMETER	4.5-5.5	<2.7	1.3	Up to 1.6	28-40	40-100	<0.6
PATIENT		4.0	1.3		35		0.1
CANINE CARDIAC PARAMETERS	HR (BPM)	AV VMAX (m/s)	PV MAX (m/s)	BODY WEIGHT	LAD LA MAX 4 Chamber	LVIDd Avg; 2D and m-mode short axis (cm)	LVIDs Avg; 2D and m-mode short axis (cm)
NORMAL PARAMETER	50-100	0.7-1.7	0.7-1.6				
PATIENT			60		2.8	2.0	

**Cardiac Presentation**

**INTERPRETED BY**

Eric Lindquist, DMV DABVP, Cert. IVUSS

**IMAGING PERFORMED BY**

Jenn

**HOSPITAL NAME**

Rockaway Animal Hospital

**REFERRING VET**

Dr Schiess

The echocardiogram presented a prominent right heart with mild right ventricular hypertrophy, without significant tricuspid regurgitation, and normal right atrial size. No evidence of neoplasia was noted in the right auricle, or elsewhere in the heart. The pulmonary artery was uniformly prominent with mildly depressed pulmonic velocity measured on PW Doppler. No overt heartworms were noted in the main or visible deep pulmonary arteries. Yet theoretically heartworms could be present in the deep pulmonary vasculature out of visible sonographic range. More likely, however, this prominent right heart is due to excessive intra-thoracic pressures caused by chronic respiratory disease or potentially excessive intra-thoracic fat (Pickwickian syndrome). The left heart demonstrated a linear ventricular septum. Contractility was functionally adequate demonstrated by the FS% measurement. The cranial and caudal mitral valve leaflets presented vegetative thickening consistent with endocardiosis. Doppler indicated measurable insufficiency. No significant left atrial dilation was noted. The left ventricular outflow demonstrated normal flow patterns and velocities through the aortic valve. No evidence of tumor, pericardial or pleural effusion was noted. The visible extra-cardiac tissues were uniformly linear without evidence of masses, infiltrative or inflammatory mediastinal tissue. No evident arrhythmic activity was noted during the exam. The pulmonary artery was dilated to 2.2 cm in width. Right ventricular hypertrophy noted. Severe tricuspid insufficiency noted. Mild hepatic vein dilation noted. Prolapsed anterior tricuspid leaflet noted.

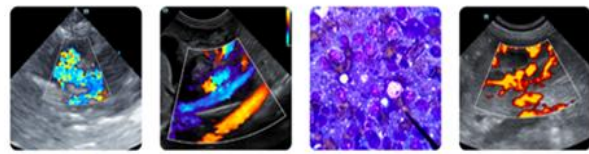
**ULTRASONOGRAPHIC FINDINGS**

**INVOICE**

24157

**DATE**

03/11/2026



**PATIENT**

Oliver Woconish

- Cor pulmonale / right-sided cardiac enlargement with pulmonary hypertension and hepatic vein dilation
- Normal left heart with mild mitral insufficiency

**SPECIES**

Canine

**BREED**

Chi

**SEX**

MN

**AGE**

13

**WEIGHT**

15

**INTERPRETED BY**

Eric Lindquist, DMV  
DABVP, Cert. IVUSS

**IMAGING PERFORMED BY**

Jenn

**HOSPITAL NAME**

Rockway Animal Hospital

**REFERRING VET**

Dr Schiess

**INVOICE**

24157

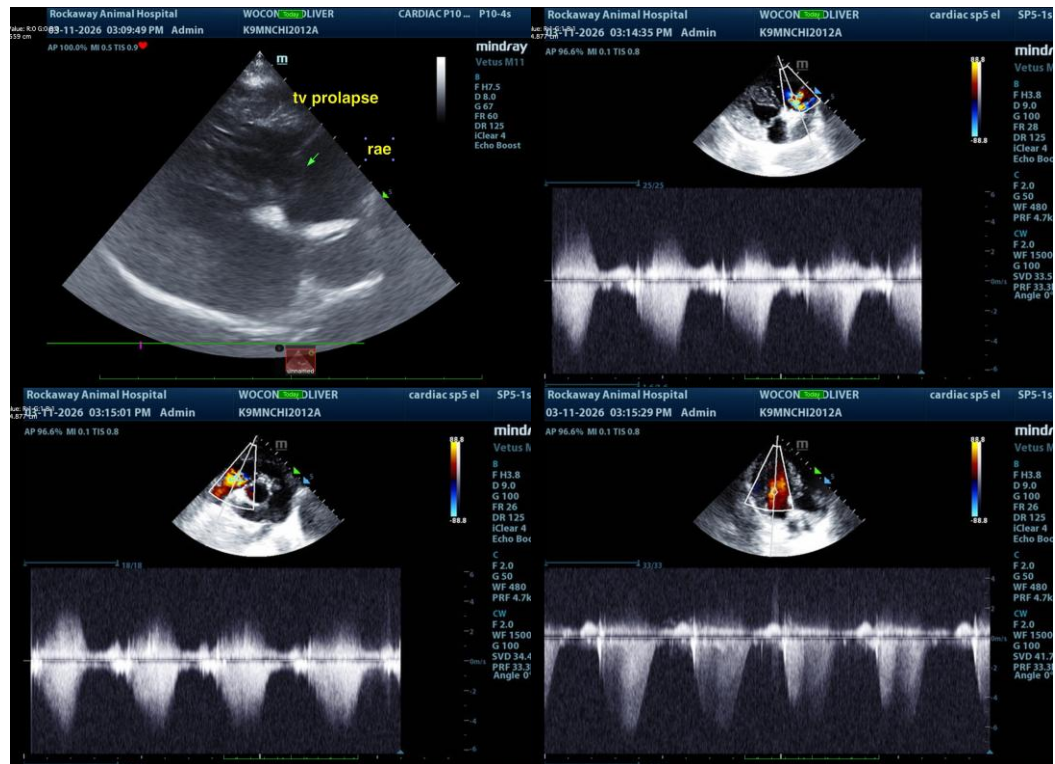
**DATE**

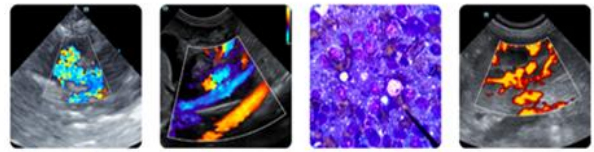
03/11/2026

**INTERPRETATION OF THE FINDINGS & FURTHER RECOMMENDATIONS**

Recommend serial blood pressures in this patient. Pulmonary edema lines noted in this patient; however the pulmonary edema or pulmonary B-lines are non-cardiogenic in nature. The heart is likely enlarged and pulmonary hypertension secondary to primary respiratory disease. Primary respiratory protocol warranted. In addition I recommend initiating sildenafil at 1 mg/kg BID over a 2 week period and then increasing to 1.5 mg/kg BID with recheck echocardiogram after 4 weeks total.

Primary respiratory protocol based on radiographic findings.





**PATIENT**

Oliver Woconish

**SPECIES**

Canine

**BREED**

Chi

**SEX**

MN

**AGE**

13

**WEIGHT**

15

**INTERPRETED BY**

Eric Lindquist, DMV  
DABVP, Cert. IVUSS

**IMAGING PERFORMED BY**

Jenn

**HOSPITAL NAME**

Rockaway Animal  
Hospital

**REFERRING VET**

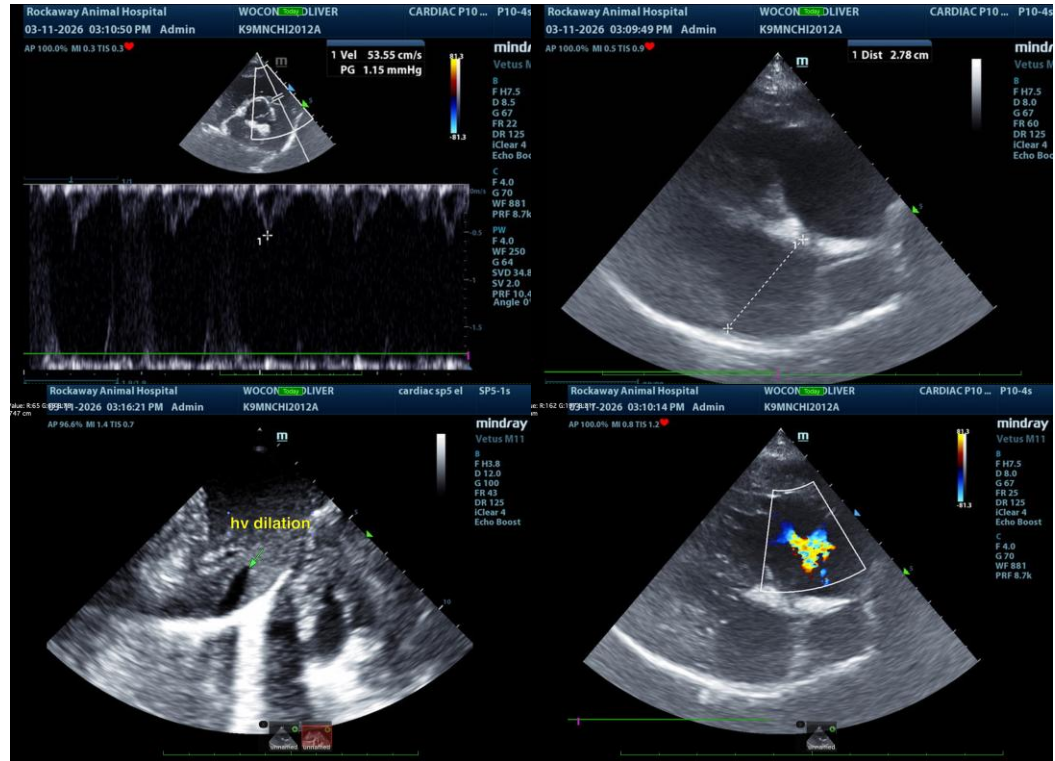
Dr Schiess

**INVOICE**

24157

**DATE**

03/11/2026



The information and recommendations provided are based on the images presented by the referring veterinarian/sonographer. No evaluation can be communicated regarding pathology that was not visible in the image/video clips provided.

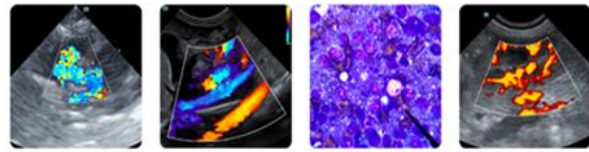
Thank you for this referral. If the clinical or image interpretation does not parallel your findings or if I can be of any further assistance, please contact me.

Eric Lindquist, DMV, DABVP(CFM), Cert. IVUSS,  
CEO, Owner, Founder -- SonoPath.com  
info@SonoPath.com

**Right Heart Disease-General Considerations**

<http://www.sonopath.com/RightHeartDisease>

**Description:** Right heart disease is often an incidental finding, which can be either cardiogenic or secondary to respiratory or systemic disease. The coughing patient with right heart disease may present with primary respiratory disease (i.e., bronchial collapse, collapsing trachea, pneumonitis) and suffer from secondary pulmonary hypertension (PHT). Concurrent mitral valve disease and chronic left-sided congestive heart failure (CHF) might also lead to PHT. The dyspeic patient with right heart enlargement might have pulmonary hypertension due to airway disease, chronic CHF, parenchymal lung disease (e.g. pulmonic fibrosis), or a cardiac shunt with secondary PHT and shunt reversal.



<b>PATIENT</b>	Primary cardiac causes of right heart enlargement include: tricuspid dysplasia/degeneration; pulmonic stenosis; pulmonic insufficiency; atrial or septal defects; patent ductus arteriosus; right auricular masses; and pericardial peritoneal diaphragmatic hernias. The second most common cause of right-sided enlargement is secondary PHT, which results in high-velocity tricuspid insufficiency (TR vel.>2.8 m/sec) and pulmonic insufficiency due to diseases that cause increased pulmonary vascular resistance or increased pulmonary wedge pressures. The most common cause of secondary PHT is left-sided heart failure (LHF), which presents radiographically as a more globoid-shaped heart with marked left atrial and ventricular enlargement. There are also signs of left-sided CHF as opposed to a simple prominent cranial waist or reverse D radiographic presentation.
Oliver Woconish	
<b>SPECIES</b>	
Canine	
<b>BREED</b>	Secondary, non-cardiac causes of PHT include: acute or chronic respiratory disease; pulmonary thromboembolic disease; thoracic neoplasia; excessive thoracic fat deposition (e.g. Pickwickian syndrome, which leads to chronic hypoxia); brachycephalic syndrome; high altitude disease; heartworm disease; and primary vascular disease.
Chi	
<b>SEX</b>	<b>Clinical Signs:</b> The most common presenting symptoms of right heart disease are collapse, syncope, intermittent or constant acute respiratory distress (e.g. thromboembolic disease), and exercise intolerance.
MN	
<b>AGE</b>	<b>Diagnostics:</b> Physical examination may reveal a right-sided apical heart murmur and/or a cranial left heart murmur, a split S2, jugular distension, ascites, and signs consistent with respiratory disease (i.e., cough, wheeze, tracheal collapse, tachypnea). Radiographic findings may reveal an enlarged right atrium, right ventricle, and/or primary/secondary branches of the pulmonary artery. In cases of PHT, an enlarged or engorged pulmonary artery is often present. Tortuous arteries or those that suddenly terminate can indicate the presence of thromboembolic disease or heartworms. An interstitial pattern might indicate the presence of pulmonary parasitism or primary interstitial lung disease. Pulmonic stenosis is suspected if the pulmonic segment is enlarged. ECG findings include tall P and S waves with a right axis shift.
13	
<b>WEIGHT</b>	
15	
<b>INTERPRETED BY</b>	<b>Treatment:</b> Please refer to the chapter "Pulmonary Hypertension" for therapeutic recommendations.
Eric Lindquist, DMV DABVP, Cert. IVUSS	
<b>IMAGING PERFORMED BY</b>	<b>References:</b> Oyama MA, Rush JE, Rozanski EA, et al. Assessment of serum N-terminal pro-B-type natriuretic peptide concentration for differentiation of congestive heart failure from primary respiratory tract disease as the cause of respiratory signs in dogs. <i>J Am Vet Med Assoc</i> 2009;235:1319-25.
Jenn	Rozanski E. Interstitial lung disease in small animals. Proceedings from American College of Veterinary Internal Medicine Forum, Denver, CO, June 15-18, 2011.
<b>HOSPITAL NAME</b>	Zoia A, Augusto M, Drigo M, Caldin M. Evaluation of hemostatic and fibrinolytic markers in dogs with ascites attributable to right-sided congestive heart failure. <i>J Am Vet Med Assoc</i> 2012;241:1336-43.
Rockaway Animal Hospital	
<b>REFERRING VET</b>	
Dr Schiess	
<b>INVOICE</b>	
24157	
<b>DATE</b>	
03/11/2026	